Case report

Ocular rosacea with corneal thinning in a 19-year-old male patient. Case report.

Ramírez S. Andrea P[1,2], Guerrero B. María V[1,3], Delgado A. Deivis J[4,5]

ABSTRACT

Ocular rosacea is a chronic inflammatory disorder that may involve the eyelids, conjunctiva, and cornea. Diagnosis is mainly clinical and may be delayed when skin manifestations are mild or absent. A 19-year-old male patient with a history of cutaneous rosacea presented with bilateral ocular burning, foreign body sensation, and decreased visual acuity.Ophthalmologic examination revealed bilateral anterior blepharitis, tarsal gland dysfunction, xerophthalmia, dry eye symptoms, conjunctival hyperemia, and superficial corneal vascularization associated with peripheral stromal thinning associated with dry eye syndrome. Treatment included eyelid hygiene, eye ocular lubricants lubrication, topical fluorometholone, and oral doxycycline, resulting in with progressive clinical improvement. Ocular rosacea represents a diagnostic challenge due to its variable presentation. Early recognition of inflammatory sings of the eyelid margin inflammation and corneal involvement is essential to prevent visual sequelae.

Keywords: Blepharitis; Cornea; Dry eye syndrome; Meibomian glands; Rosacea

ACTA CIENTIFICA ESTUDIANTIL

Andrea Paola Ramirez Sanchez (1,2)
ORCID: 0009-0006-8384-9801

María Verónica Guerrero Barrios (1,3)
ORCID: 0009-0009-5282-0055

Dr. Deivis José Delgado Alvares (4.5)
ORCID: 0009-0006-0297-3326

1. Medical Student. Faculty of Medicine, University of the Andes, San Cristóbal Extension, Venezuela

2. University Scientific Association of Medical Students of ULA Táchira

3. BSc. in Nursing, from the Rómulo Gallegos National Experimental University (UNERG)

4. Surgeon. University of the Andes

5. Ophthalmologist. High-specialty fellowship in cornea and refractive surgery. National Autonomous University of Mexico

Editora: Lourdes Delgado
ORCID: 0000-0003-0910-5434

Date of receipt: 09/13/25
Acceptance date: 09/10/26

To cite this article:

Ramírez S. Andrea P, Guerrero B. María V, Delgado A. Deivis J. Ocular rosacea with corneal thinning in a 19-year-old male patient. Case report. Acta Cient Estud. 2026; 18(2):e5

ISSN 2542-3428

Introduction

Ocular rosacea is a chronic inflammatory condition associated with rosacea that primarily affects the eyelid margin, the conjunctiva, and the cornea. It can occur in isolation or coexist with cutaneous involvement, which makes early diagnosis difficult [1]. The pathophysiological mechanism is related to dysfunction of the innate immune system, vascular abnormalities, and a chronic inflammatory response in the tarsal glands, promoting the development of persistent blepharitis and dry eye syndrome [2].

Epidemiologically, ocular rosacea is most commonly observed in adults in their 40s and 50s [3]; therefore, its occurrence in young patients represents a clinically significant finding.

Corneal involvement, characterized by superficial vascularization and stromal thinning, is one of the manifestations with the greatest prognostic significance, as mentioned in **Table 1**, "Major and Minor Features of Rosacea," from the recommendations of the ROSCO Global Panel.

This case is significant because it describes ocular rosacea with corneal involvement in a 19-year-old male patient, which is a rare presentation and highlights the importance of early diagnosis.

Case presentation

This is a 19-year-old male patient, occupation not reported, with an unspecified skin phototype, who presented to an ophthalmology clinic with eye burning, a foreign body sensation, and decreased visual acuity as the primary reason for the visit.

The current condition had been present for several weeks, with a history of erythematous, papular, and pustular skin lesions on the face **[Figures 1 and 2]**.

The patient reported that the dermatological manifestations appeared first, followed later by the ocular symptoms; there was no simultaneous onset of both presentations.

Table 1. Diagnostic characteristics, major and minor characteristics of rosacea. From the recommendations of the global ROSCO panel

Diagnostic characteristics	Major characteristics	Minor characteristics
Persistent centrofacial erythema associated with periodic intensification due to possible triggering factors	Transient centrofacial erythema / redness	Burning sensation on the skin
Fimatous changes	Inflammatory papules and pustules	Sensation of tingling on the skin
	Telangiectasias	Edema
	Telangiectasia of the eyelid margin Blepharitis Keratitis/conjunctivitis/ sclerokeratitis	Feeling of dryness in the skin

Fuente: Consenso sobre la Rosácea (ROSCO) (2017)

Figure 1. Thickened, irregular borders (red arrow) with telangiectasias (blue arrow) and hyperkeratinization of the glandular ducts (green arrow)

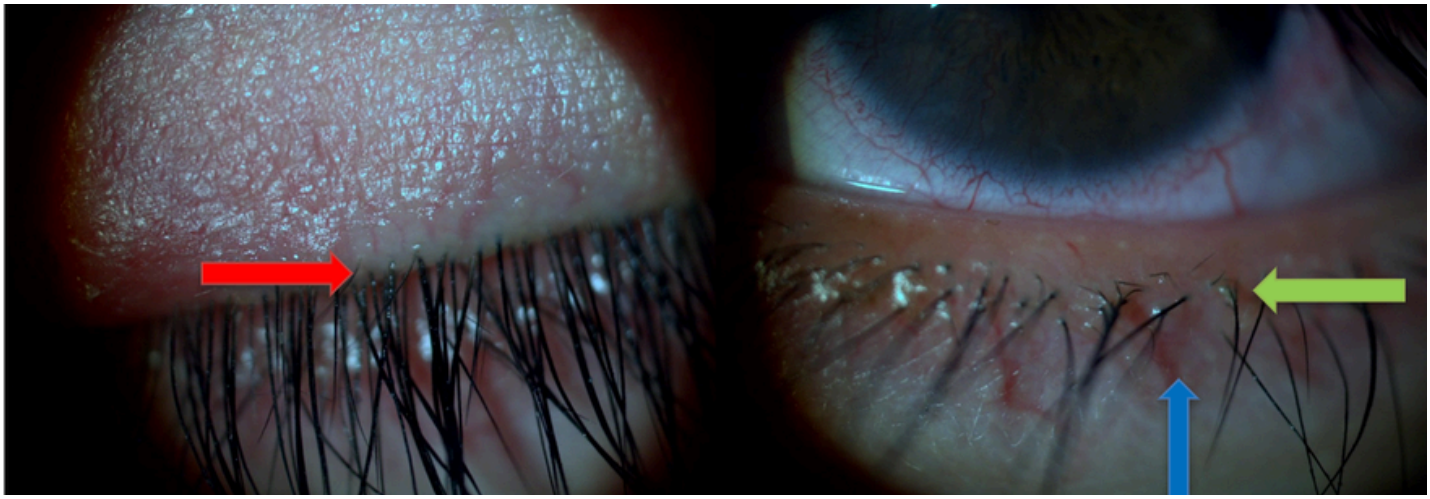

Figure 2. Hyperemic conjunctiva with vasodilation (red arrow), small nodule (blue arrow), and superficial corneal vascularization (green arrow)

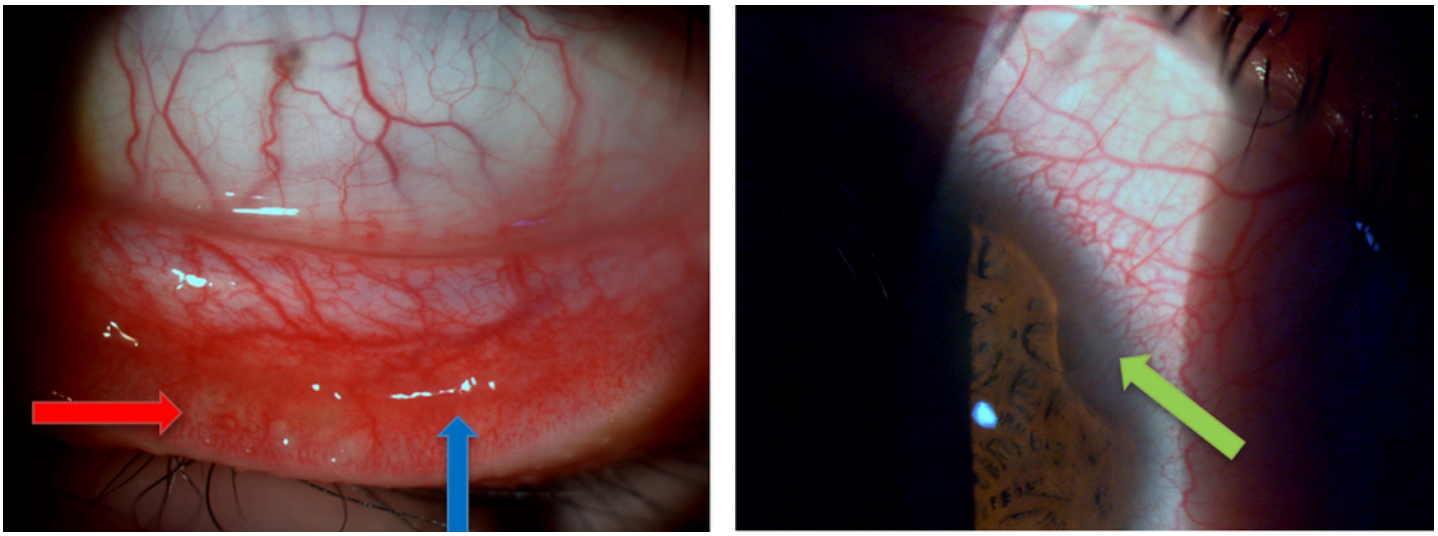

The ocular manifestations were bilateral and included persistent eye burning, xerophthalmia, and discomfort associated with a foreign body sensation.

Ophthalmological examination revealed bilateral anterior blepharitis associated with tarsal gland dysfunction, telangiectasias along the eyelid margin, and chronic inflammatory involvement of the eyelid margin **[Figures 2]**. Furthermore, visual acuity testing yielded results of 20/80 in the right eye (OD) and 20/100 in the left eye (OI).

The patient had a history of cutaneous rosacea previously diagnosed on an unspecified date, for which dermatological treatment based on skin hygiene and oral antibiotic therapy had been prescribed; the patient reported partial adherence to the treatment.

The diagnosis of ocular rosacea was established clinically during the ophthalmologic evaluation, based on findings of chronic blepharitis, tarsal gland dysfunction, and superficial corneal involvement **[Figures 3 and 4]**.

Figure 3. Corneal thinning

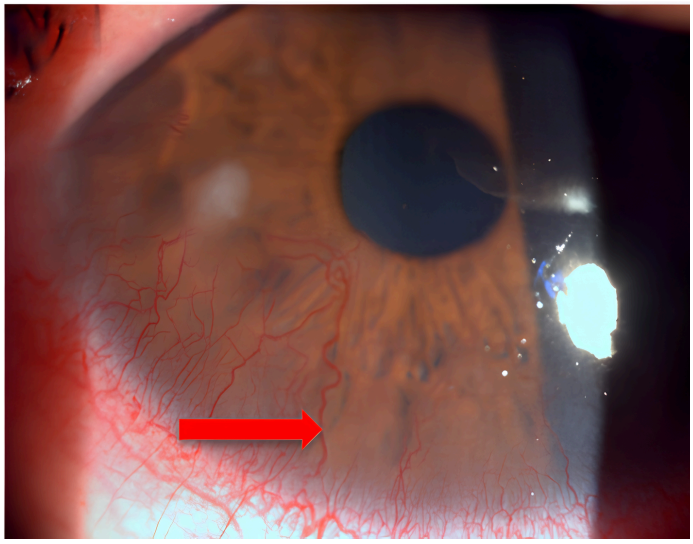

Figure 4. Punctate keratitis

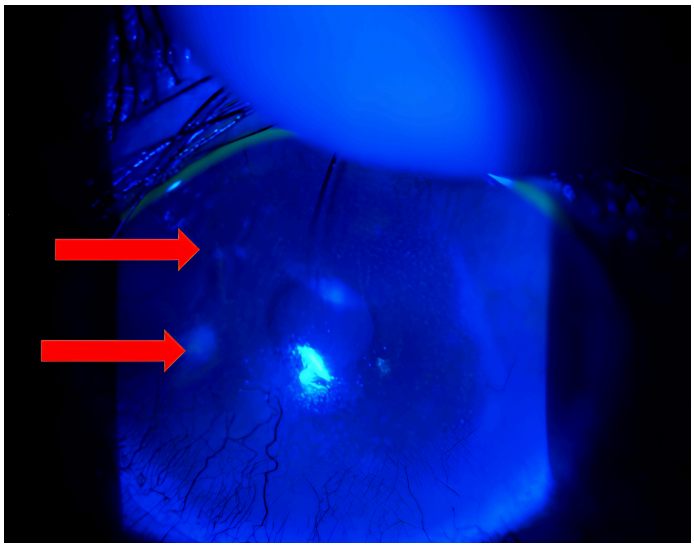

The treatment regimen consisted of daily eyelid hygiene, artificial tears (Systane®) every 6 hours, topical fluorometholone for 2 weeks, oral doxycycline 100 mg every 12 hours for 4 weeks, followed by 50 mg daily depending on clinical response, and topical Obrydex® according to a short-term anti-inflammatory regimen. Periodic clinical follow-up was recommended to assess the evolution of the ocular surface and control of the inflammatory process.

In the evaluation of results, the patient reported a progressive reduction in the burning sensation and foreign body sensation, as well as a subjective improvement in visual acuity over the weeks following the start of treatment. Specialized examination revealed a reduction in eyelid and conjunctival hyperemia, as well as stabilization of corneal involvement.

Follow-up was conducted on an outpatient basis, with an emphasis on treatment adherence and education regarding eyelid care. It was determined that ocular rosacea requires long-term maintenance treatment due to its chronic nature and the possibility of symptomatic recurrence

Discussion

Ocular rosacea is a chronic inflammatory condition that is difficult to diagnose due to its heterogeneous clinical presentation and the possible absence of obvious cutaneous manifestations.

This condition can affect structures of the anterior segment, including the eyelid margin, the conjunctiva, and the cornea, leading to significant visual morbidity if it is not identified and treated in a timely manner [1].

The pathophysiology of ocular rosacea is associated with innate immune dysfunction, vascular abnormalities, and chronic inflammatory processes affecting the tarsal glands and the ocular surface.

The overexpression of inflammatory mediators and the activation of immune cells such as neutrophils, T lymphocytes, and mast cells contribute to the perpetuation of tissue damage, promoting the development of anterior blepharitis, dry eye syndrome, and progressive corneal changes [2].

From an epidemiological perspective, rosacea is most commonly diagnosed in adults in their 40s and 50s; however, the present case is noteworthy because it involves a 19-year-old male patient, an age group in which ocular rosacea is rare and may go clinically unnoticed [3].

Corneal involvement represents one of the most serious manifestations of ocular rosacea. The superficial vascularization and stromal thinning observed in the patient are findings associated with chronic inflammation of the ocular surface, which can progress to corneal scarring, ulceration, or even perforation in severe cases [4].

The diagnosis of ocular rosacea is primarily clinical and requires a high index of suspicion. The absence of specific laboratory tests underscores the importance of a detailed ophthalmologic evaluation, especially in patients with chronic refractory blepharitis or persistent dry eye syndrome.

In the present case, the coexistence of anterior blepharitis, tarsal gland dysfunction, and corneal abnormalities allowed for a differential diagnosis with other conditions such as seborrheic dermatitis, allergic conjunctivitis, and demodicosis [5].

Treatment of ocular rosacea must be individualized and generally requires a stepwise approach that includes eyelid hygiene measures, ocular lubrication, and topical or systemic anti-inflammatory therapy. Oral doxycycline has been widely used for its anti-inflammatory effect on tarsal gland function and its modulation of the local immune response [6].

The chronic and recurrent nature of ocular rosacea calls for long-term maintenance strategies, as well as patient education regarding treatment adherence and the identification of environmental and dietary triggers.

Conclusions

Ocular rosacea is a chronic inflammatory disease that can affect the ocular surface and lead to significant visual complications if not diagnosed early. Its variable clinical presentation and the possible absence of cutaneous manifestations make it difficult to recognize.

This case highlights the importance of considering ocular rosacea in young patients with chronic blepharitis, xerophthalmia, and inflammatory corneal involvement. Multidisciplinary evaluation and timely anti-inflammatory treatment are essential for controlling disease progression and improving the patient's quality of life.

Finally, long-term clinical follow-up is essential due to the recurrent nature of ocular rosacea and the risk of corneal complications.

Ethical considerations

The study was conducted in accordance with the ethical principles of biomedical research established in the Declaration of Helsinki. Written informed consent was obtained from the patient for the publication of the clinical case and the use of images for academic and scientific purposes. The confidentiality of personal data was ensured, and any information that could identify the patient was omitted.

Conflict of interest

The author declares that there are no financial, academic, or personal conflicts of interest that may have influenced the preparation or publication of this case report.

References

1. Lucero Saá F, Cremona F, Chiaradia P. Association Between Skin Findings and Ocular Signs in Rosacea. Turk J Ophthalmol. 2021 Dec 28;51(6):338-343. doi: 10.4274/tjo.galenos.2021.05031. PMID: 34963260; PMCID: PMC8715657.
2. Zierl S, Hildebrand A, Guertler A, Jansen T, Ständer S, Homey B, et al. Clinical clues to identify patients with ocular rosacea: a Germany-wide epidemiologic analysis. Int J Dermatol. 2022;61(7):880-5. doi: 10.1111/ijd.16235.
3. Tavassoli S, Wong N, Chan E. Ocular manifestations of rosacea: a clinical review. Clin Exp Ophthalmol. 2021;49(2):104-17. doi: 10.1111/ceo.13900.
4. Redd TK, Seitzman GD. Ocular rosacea. Curr Opin Ophthalmol. 2020;31(6):503-7. doi: 10.1097/ICU.0000000000000706.
5. Andreas M, Fabczak-Kubicka A, Schwartz RA. Ocular rosacea: an under-recognized entity. Ital J Dermatol V

6. Medina Vicent NA, Vega Memije ME, Arenas Guzmán R. Ocular rosacea. Rev Cosmet Dermatol [Internet]. 2024 [cited 2 Mar 2026]. Available at: https://www.medigraphic.com/pdfs/cosmetica/dcm-2024/dcm243k.pdf.