

## Artículos

- [<sup>1</sup>H Magnetic Resonance Spectroscopy assessment of the radiochemotherapy response in Gliomatosis Cerebri.](#)
- [Introduction](#)
- [Materials and methods](#)
- [Results](#)
- [Discussion](#)
- [References](#)

### **Arturo Alvarado**

[arturoalvaradopisani@gmail.com](mailto:arturoalvaradopisani@gmail.com)

Universidad Central de Venezuela,  
School of Medicine, Experimental  
Medicine Institute, Pharmacology and  
Toxicology Department,  
Neurospectroscopy Branch. Caracas,  
Venezuela. and Centro Diagnóstico  
Docente Las Mercedes, Caracas,  
Venezuela.

### **Jomer García**

ASODIAM Association for Medicine  
Diagnosis, Maracay, Venezuela.

### **María Daniela González**

ASODIAM Association for Medicine  
Diagnosis, Maracay, Venezuela.

### **Belén Torres**

ASODIAM Association for Medicine  
Diagnosis, Maracay, Venezuela.

### **Amanda Peña**

ASODIAM Association for Medicine  
Diagnosis, Maracay, Venezuela.

### **Mariangela Alvarado**

6th year Student, Luis Razetti School of  
Medicine, Universidad Central de  
Venezuela.

### **Imagenología**

## <sup>1</sup>H Magnetic Resonance Spectroscopy assessment of the radiochemotherapy response in Gliomatosis Cerebri.

Fecha de recepción: 10/02/2010

Fecha de aceptación: 28/03/2010

El presente estudio fue diseñado para evaluar los cambios metabólicos que resultan luego de la administración de radioquimioterapia en un caso de Gliomatosis Cerebri (GC) utilizando la técnica de Espectroscopia de Hidrógeno por Resonancia Magnética (ERM). Se estudió una paciente con GC luego de obtener su consentimiento informado y la aprobación de la comisión de ética. Ella recibió radiación en todo el cerebro hasta alcanzar una dosis total de 55 Gy en 30 sesiones durante 60 días. Luego de la radioterapia recibió por vía oral 100 mg de Temozolomida durante 5 días consecutivos cada 28 días. La ERM fue realizada al inicio del tratamiento, luego a los 3, 12 y 24 meses post-tratamiento en un equipo de 1.5 Tesla. La ERM Multivoxel se realizó utilizando un tiempo de repetición de 1500 milisegundos, tiempo de eco de 30 milisegundos y 6 adquisiciones. Las señales metabólicas provenientes de Lípidos (Lip), Lactato (Lac), N-Acetilaspártato (NAA), Creatina (Cr), Colina (Cho) y mio-Inositol (ml) fueron detectadas y se calcularon las relaciones NAA/Cr, Cho/Cr, ml/Cr y NAA/Cho. El diagnóstico de GC fue confirmado mediante biopsia estereotáxica en el área en la cual se obtuvo el valor más elevado de la relación Cho/Cr. Se observó un descenso del cociente ml/Cr y un incremento de la relación NAA/Cr asociados con la reducción de la masa tumoral posterior a la radioquimioterapia. Basados en nuestros resultados concluimos que la ERM puede ser una herramienta de utilidad para evaluar la respuesta terapéutica de la GC cuando se utiliza radiación y quimioterapia. La asociación entre el descenso de la relación ml/Cr y la respuesta parcial de la lesión podrían ayudar al desarrollo de formas más adecuadas de tratamiento y a predecir su eficacia para mejorar la sobrevida de los pacientes con GC.

**Palabras Claves:** Gliomatosis Cerebri, Espectroscopia por Resonancia Magnética, Radioquimioterapia, Temozolomida.

### **Title**

Evaluación de la respuesta a la radioquimioterapia en gliomatosis cerebri mediante espectroscopia de hidrógeno por resonancia magnética.

### **Abstract**

This study was designed to perform <sup>1</sup>H Magnetic Resonance Spectroscopy (MRS) on a Gliomatosis Cerebri (GC) patient who received radiochemotherapy, in order to assess brain metabolic changes that result from treatment. One patient with GC was studied after her informed consent was obtained. She was treated with whole brain radiation therapy receiving a total dose of 55 Gy in 30 fractions over 60 days. After radiotherapy, she received Temozolomide 100 mgs for 5 days each 28 days. MRI and MRS were performed at the beginning of treatment and after 3, 12 and 24 months of therapy on a 1.5 T scanner. Chemical-Shift Imaging (CSI) was concluded using 1500/30/6 (TR/TE/Acquisitions). Metabolic signals from Lipids (Lip), Lactate (Lac), N-Acetylaspartate (NAA), Creatine (Cr), Choline (Cho), and myo-Inositol (ml) were detected and NAA/Cr, Cho/Cr, ml/Cr and NAA/Cho ratios were calculated. The GC diagnosis was confirmed by a stereotactic biopsy of the area where the

Cho/Cr ratio reached the highest value. A decrease in the ml/Cr ratio was found in association with tumor mass reduction after radiochemotherapy. NAA/Cr ratio was increased after radiotherapy as well. Based on those results we conclude that MRS may provide a useful tool for monitoring the therapeutic response in GC when brain radiation and chemotherapy is applied. The link between the decrease of ml/Cr ratio and the partial response of the tumor may provide a fertile ground for developing better forms of therapy and predicting its efficacy to improve GC patients' survival.

### **Key Word**

Gliomatosis Cerebri, Magnetic Resonance Spectroscopy, Radiochemotherapy, Temozolomide.

## **<sup>1</sup>H Magnetic Resonance Spectroscopy assessment of the radiochemotherapy response in Gliomatosis Cerebri.**

### **Introduction**

GC is a condition that involves at least two lobes of the brain by a glial cell tumor origin with preservation of neuronal architecture <sup>(1)</sup>. Growing evidence suggests that GC is a large diffuse glioma (astrocytoma, oligodendroglioma or oligoastrocytoma) rather than a separate entity or a field cancerization <sup>(2)</sup>. The hallmark of GC is a growth pattern with predominating low cellularity with an extraordinary extension <sup>(1)</sup>. Like diffuse gliomas GC can progress to a higher grade of malignancy. The interval until progression is largely unpredictable. MR imaging shows abnormalities as diffuse signals strength with minimal or no mass effect and a lack of contrast enhancement <sup>(3)</sup>. Those findings may be nonspecific leading to a differential diagnosis that includes neoplastic, inflammatory and vascular lesions. MRS may help narrow the differential diagnosis in support of a neoplastic lesion by revealing increased Cho/Cr and Cho/NAA ratios and variably decreased NAA/Cr relation <sup>(4,5)</sup> although some nonneoplastic lesions such as encephalitis, demyelinating disease, and organizing hemorrhage may mimic these spectral changes. MRS could still help in the differential diagnosis in favor of GC by analyzing ml/Cr proportion because it can be elevated even when Cho/Cr ratio is normal <sup>(6-12)</sup>. The role of whole brain radiotherapy regarding overall survival is unclear <sup>(13-15)</sup> whereas chemotherapy appears beneficial, at least for some patients <sup>(16-18)</sup>.

**Case presentation:** A 70 year-old woman presenting with a history of headache, lack of balance, personality changes, left hand tremor and left-sided weakness, was admitted in the unit. The patient was studied after her informed consent was obtained. She was treated with whole brain radiation therapy receiving a total dose of 55 Gy in 30 fractions over 60 days. After radiotherapy, she received Temozolomide 100 mgs for 5 days each 28 days <sup>(19)</sup>.

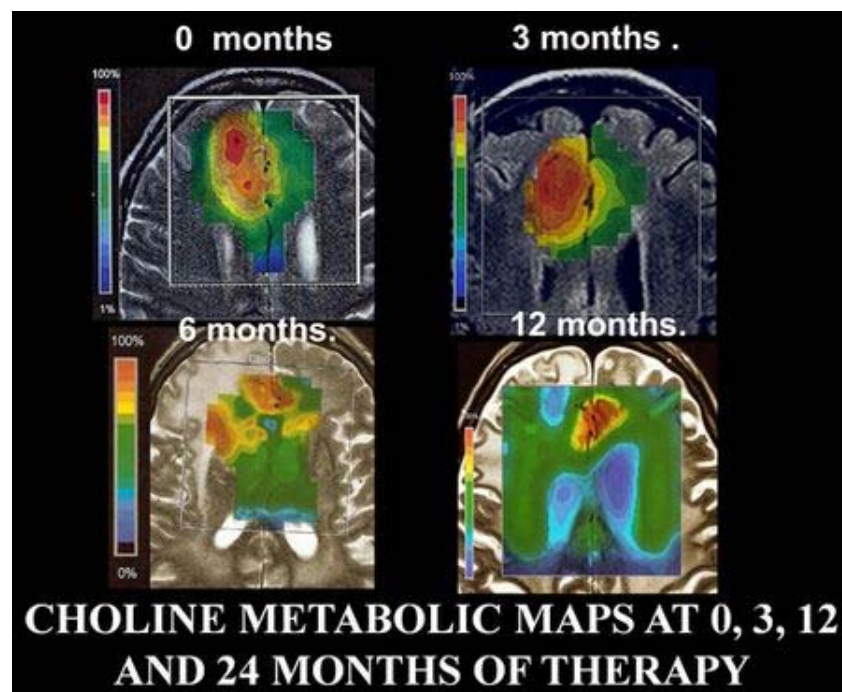
### **Materials and methods**

MRI and MRS were performed at the beginning and after 3, 12 and 24 months of therapy on a 1.5 T scanner. A localizing Sagittal T1-weighted image was obtained, followed by Axial and Coronal T1-weighted. Axial T2-weighted as well as DARK FLUID or FLAIR images was also acquired. The hybrid Multivoxel 2D Chemical Shift Imaging (CSI) technique uses a Point-Resolved Spectroscopy (PRESS) Double Spin Echo scheme for pre-selection of a Volume of Interest (VOI) that is usually defined to include the abnormality as well as normal appearing brain tissue. We used CHESS for water suppression. In order to avoid a contribution to the spectra from fat signals, the VOI is completely enclosed within the brain and positioned at the center of the phase-encoded Field of View (FOV). VOI consisted of an 80 mm x 80 mm region placed within a 160 mm x 160 mm FOV on a 10 mm to 20 mm slice. A 16 x 16 phase-encoding matrix gives an 8 x 8 array of spectra in the VOI with a plane resolution of 10 mm x 10 mm. The

parameters used were 1500/30/6 (TR/TE/Acquisitions). Other settings included a Hamming filter, number of sampling points NP = 1024, BW = 1kHz, preparatory scans = 6, delta frequency = -2.7 ppm. Data underwent apodization through a 1.0 Hz Lorentzian filter, Fourier transformation in time and space, and phase correction (6). Lipids (Lip), Lactate (Lac), N-Acetylaspartate (NAA), Creatine (Cr), Choline (Cho) and *myo*-Inositol (mi) intensity signals were detected. NAA/Cr, Cho/Cr, mi/Cr and Cho/NAA ratios were calculated. The GC diagnosis was confirmed by a stereotactic biopsy of the area where the Cho/Cr ratio reached the highest value (intense red color in Figure 1).

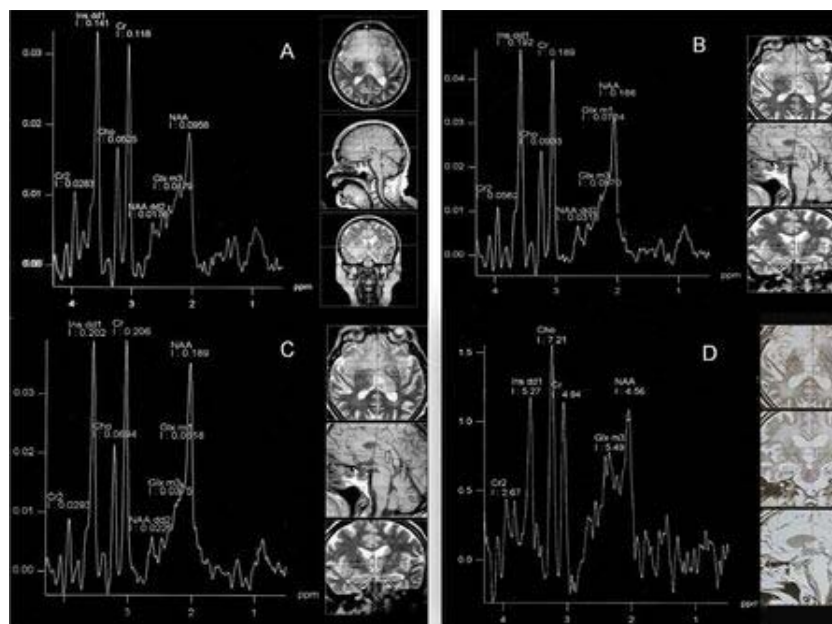
## Results

Figure 1 represents metabolic maps for Choline obtained during the 24 months of observation when MRS was performed at the Frontal Cortex. The stereotactic biopsy was taken at the intense red zone at the image identified as 0 months.



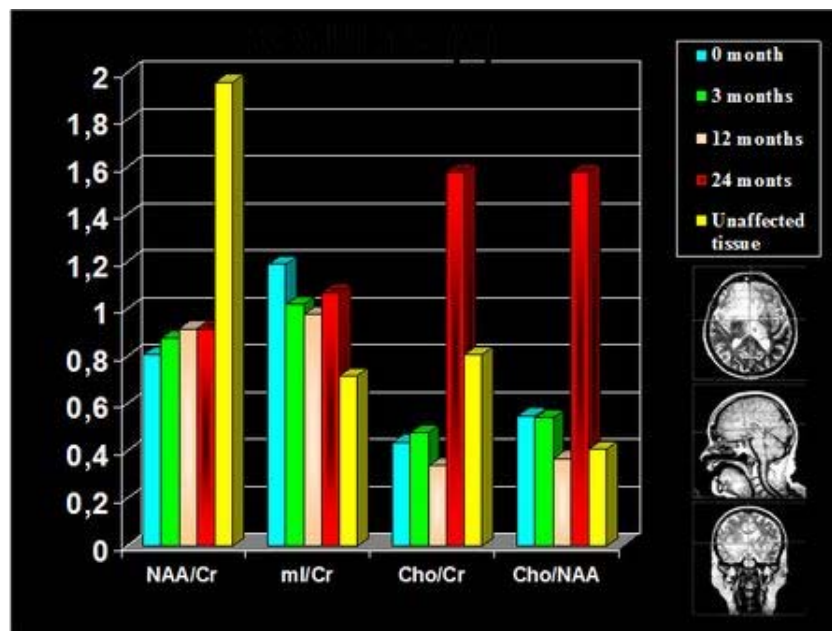
**Figure 1. Choline metabolic maps at four different times. Note the changes in the Cho intensity as an effect of the radiochemotherapy treatment.**

Figure 2 represents the spectral patterns evolution of the GC patient through 24 months of observation: A shows the first study performed before begin any treatment. We can observe the changes produced in the metabolite signal intensity as an effect of the whole brain radiation therapy (B and C) and after temozolomide treatment (D).



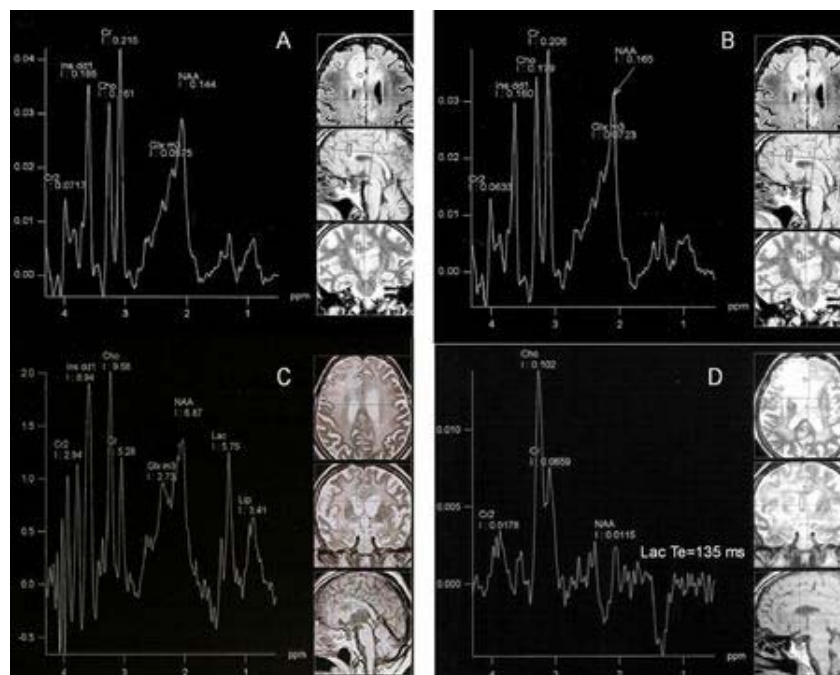
**Figure 2.** The composite image represents this specific sequence: A: Spectral profile obtained at the time in which GC diagnose was made (without treatment). Spectral patterns obtained after 3 months (B) and 12 months (C) of whole brain radiation therapy. D shows the MRS after 24 months of radiotherapy and 12 months of temozolomide treatment. After the combined effect of radiochemotherapy we clearly noticed a significant reduction in mI/Cr ratio (D).

Figure 3 illustrate the ratios evolution during the 24 months of observation. We observed an increase in the NAA/Cr and NAA/Cho ratios as a radiotherapy effect. The red bars represent the ratios after the administration of radiochemotherapy.



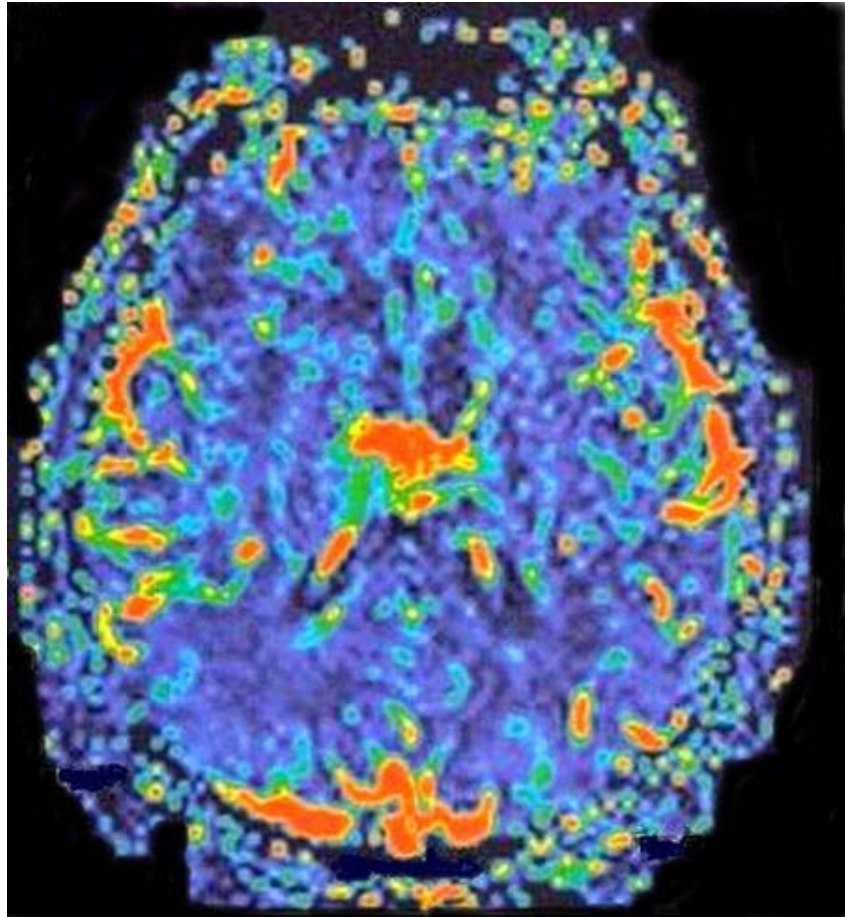
**Figure 3.** The bars represents metabolic ratios for NAA/Cr, mI/Cr, Cho/Cr and NAA/Cho at the region of interest located at the axial, sagital and coronal slices.

Figure 4 shows the spectral patterns evolution of the GC patient when MRS was performed at the righth Frontal Parietal region trough 24 months of observation. A. shows the first study performed before any treatment was started. Changes produced in the metabolite signal intensity as an effect of the whole brain radiation therapy can be seen. (B and C) and the confirmation of a Lactate peak using a long an echo time of 135 msec (D). The appearance of Lactate and lipids peaks probably represents radionecrosis.



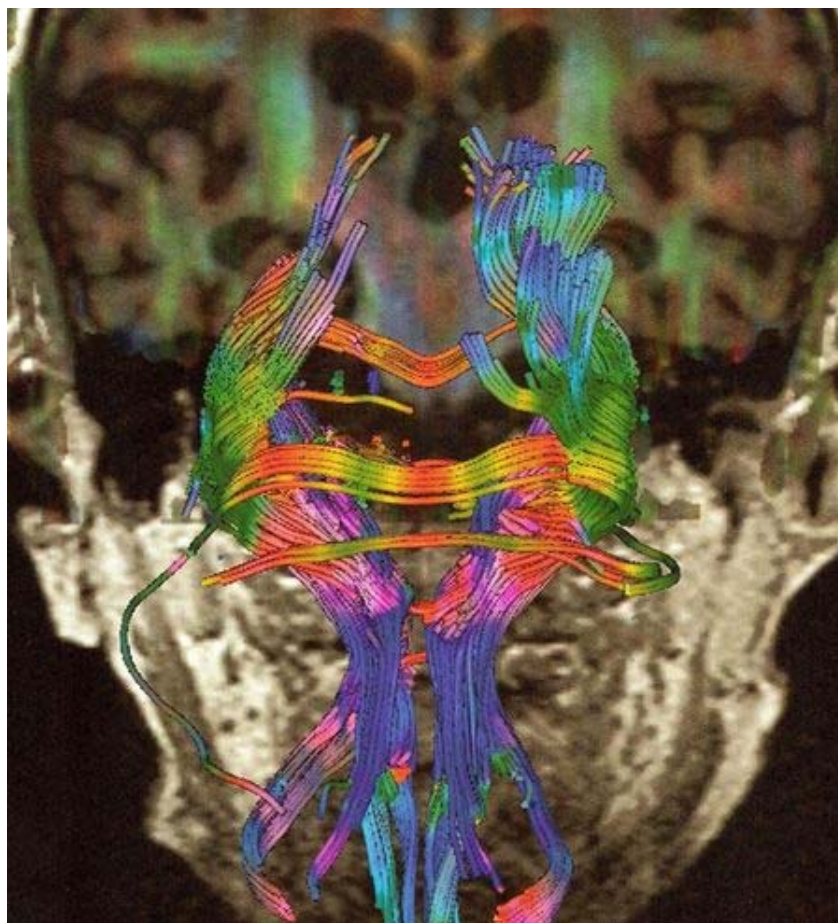
**Figure 4.** The composite image located at the Right Frontal Parietal Region represents this specific sequence: **A** Spectral profile obtained at the time when GC was diagnosed (without treatment). **B** corresponds to spectral patterns obtained after 12 months of temozolomide treatment. **C** shows the MRS after 24 months of radiotherapy treatment and 12 months of temozolomide administration. Note the peaks for Lactate and Lipids. **D** shows the spectral pattern obtained at the same time that **C** using long echo time (135 msec) in order to corroborate Lactate presence detected as a doublet inverted peak.

Figure 5 shows the perfusion image obtained in the GC patient when gadolinium was injected in bolus. The image closely resembles the relative Cerebral Blood Volume (rCBV).



**Figure 5. Perfusion image obtained in the GC case reported. A symmetric blood volume in the region of the tumor is shown on the relative Cerebral Blood Volume (rCBV) map.**

Figure 6 illustrates the Diffusion Tensor Image (DTI) or Tractography in a superimposed Coronal View of GC case.



**Figure 6.-Diffusion Tensor Imaging (DTI) or Tractography in our GC case. This application allows the noninvasive tracking of neuronal fiber projections in a living human brain and demonstrates in this case the displacement of tracts by tumor.**

## Discussion

GC is an uncommon brain tumor characterized by a growth of glial elements and extensive infiltration of at least two lobes of the brain. Until this year more than 200 cases have been reported in the literature. The results of the present study involves some metabolic changes that must be interpreted taking in mind the pathological course of GC, the effects of the whole brain radiation therapy and the chemotherapy treatment. NAA is found only in normal nerve cells and their fibers (20). Brain tumors are thought to replace or destroy the normal NAA containing cells, thereby causing a decrease in NAA levels on MRS. Neuronal cell death caused by apoptosis or neuronal dysfunction has been suggested as an explanation of this fact. Other explanations such as neuronal response to blood-brain barrier breakdown, edema, damaged oligodendrocytes, release of cytokines, and exposure to inflammatory cells have also been suggested. Significant alterations in brain metabolites particularly a decrease in NAA, were shown to occur in normal-appearing human brain parenchyma early during radiation treatment and the amount of radiologically normal tissue increases as the tumour reduces in size. The results showed in Figure 2, 3 and 4 demonstrates about 10% increase in NAA/Cr ratio after radiotherapy application while after TMZ remains stable. This could be explained in part by the elevation rate

in NAA with time as the normal tissue returns to the site originally infiltrated diffusely by GC tumour tissue that results in invasion rather than destruction of surrounding brain tissue. If tumour cells show some kind of therapeutic response, the normal tissue may return into the space once occupied by the tumour. Sensitivity to this process will, however, be technology dependent. If the voxel is placed at the centre of a large tumour then it may require a large change in tumour volume to detect an alteration in NAA. This may reflect why NAA did not increase in some tumours that demonstrated a substantial reduction in tumour volume. Partial NAA concentration recoveries have been reported after whole-brain radiation therapy was applied. After chemotherapy, the value for NAA/Cr ratio does not differ from the obtained when whole brain radiation therapy was applied. Therefore, the increase in Cho/NAA ratio after chemotherapy may be related with the raise of the Cho signal intensity as reflected also by the increase in the Cho/Cr ratio (Figure 2 D).

MRS in brain tumours has established increased choline levels which have been associated with an increased number of cells, greater rate of cell membrane synthesis and increased cell turnover, which are processes associated with brain tumor cell division. Previous research has reported normal or unchanged Cho levels in GC (21-23). Our results agree with these previous observations. Because Cho/Cr ratio is considered to reflect membrane lipid turnover accompanying cellular proliferation, the finding of low or close to normal Cho/Cr ratio value could suggest that the GC tumor cells do not quickly proliferate. The whole brain radiation therapy does not produce any change in the Cho/Cr relation values as it is shown in Figure 2 and 4. Therefore, 12 months after beginning chemotherapy, we noticed an important increase in this ratio value. After observing the Cho/Cr proportion conduct it is possible to attribute the relatively normal values to diminished membrane lipid turnover and to a lack of cellular proliferation occurring in low-grade as compared with high-grade tumors. Tumor grade alone, however, seems unlikely to account for the Cho/Cr ratio results because the GC lesion was not strictly low grade. Other work (22) has suggested an alternative possibility: the presence of mixed oligodendroglial components in the tumor could have contributed to the unusual spectral results.

The raise in ml signal intensity has been reported previously in GC, Astrocytomas and Low Grade Gliomas (24). An increase in ml could be related to the proliferation or activation of glial cells which have been shown to synthesize ml. Many researchs have associated the ml enlarge in glial tumor to tumor proliferation (25-26). Therefore, the elevation of ml observed in our GC patient could be associated with a glial activation since moderate Cho elevation argues for a low tumor density. In a previous paper (21) it has been suggested that the loss of neurons or reversible neuronal injury is highly correlated with an increased level of ml in the brain and that glial proliferation might replace or destroy neurons. Consequently, in infiltrative areas of GC an intense glial activation is associated either with a relative decrease in neuron density or with reversible neuronal injury as already described in other diseases. The elevation of ml/Cr ratio in low grade astrocytomas is related to the hypothesis that ml is a glial marker. The mechanism that explains this rise is unclear because of the several roles played by ml in cellular metabolism. In one proposed mechanism, the elevation is attributed to changes in the phospholipid composition of glial cell membranes. It has been reported (23) that ml/Cr ratio was higher in patients with low-grade tumors, followed by control subjects, and that it was lower in patients with anaplastic tumors and Glioblastoma Multiforme.

There was an inverse relationship between Cho/Cr and ml/Cr ratios; that is, with progressive elevation of Cho/Cr proportion, the ml/Cr proportion decreased as we observed after TMZ therapy was given. NAA/Cr ratio had an inverse relation to ml/Cr relation; that is higher ml/Cr fraction correlate with lowest NAA/Cr fraction. We observed a reduction in ml/Cr ratio as a direct effect of radiotherapy (Figure 3). Therefore, ml/Cr ratio increase after chemotherapy but there is little information regarding the possibles changes that could be produced on this metabolite as an effect of radiotherapy treatment.

GC has extensive areas of hypoxia and necrosis (24,25). Lactate is the end-product of the nonoxidative glycolysis. Therefore, its presence may be correlated with poor oxygenation level or hypoxia in the tumor tissue. The presence of mobile lipids has been correlated with the formation of necrosis where cellular death results in membrane breakdown. Because of this proximity of resonance on MRS, lactate and lipids are often treated as a single metabolite, though each represents vastly different tumor biology and tissue viability (4, 27). The regions of lactate (Figure 4 C and D) most likely represent areas of hypoxic but viable tumor, whereas the regions of mobile lipid represent necrotic nonviable tissue. More interestingly, the regions of high lactate or lipid metabolite peaks were seen in close proximity, if not identical, to the areas of maximal tumor blood volume abnormality assessed by dynamic susceptibility-weighted contrast-



enhanced (DSC) MR imaging (Figure 5). It remains to be seen, however whether lactate from MRS correlates directly with histologic assessment of tumor hypoxia, such as antibody staining of hypoxia-inducible factor as shown in some reports (28). The lactate metabolite could be a surrogate marker of radioresistance in gliomas undergoing radiation therapy. Although lack of sufficient data underscores using lactate metabolite derived from MRS as a reliable biomarker of tumor hypoxia or radioresistance, robust separation of lactate and lipid metabolites in gliomas is an important step toward establishing the biologic significance of each metabolite. It is well known that in previously treated tumors the presence of lactate and lipids may represent a sequela of treatment and may not reflect the histologic grade of the tumor. Other applications like Diffusion Tensor Imaging (DTI) or Tractography were performed to complete the imaging inspection of the GC case (Figure 6). The results suggest that Tractography could be performed as an adjunct evaluation for MRS and MRI. In conclusion MRS may provide a useful tool for monitoring the therapeutic response in GC when radiochemotherapy is applied; therefore we recommend it as a complement for MRI evaluation. The link between the decrease of ml/Cr and the raise of NAA/Cr ratios with the partial response of the tumor may also provide a fertile ground for developing a based radiochemotherapy treatment and predicting its efficacy to improve GC patients' survival.

## References

- 1.- Nevin S. Gliomatosis cerebri. *Brain* 1938; 61: 170-191.
- 2.- Gillies R and Morse D. In vivo magnetic resonance spectroscopy in cancer. *Ann Rev Biomed Engin* 2005; 7: 287-326.
- 3.-Yang S, Wetzel S and Cha S. Dynamic Contrast-Enhanced T2\*-Weighted MR Imaging of Gliomatosis Cerebri. *Am J Neuroradiol* 2002; 23: 350-355.
- 4.-Lin A, Ross B, Harris K and Wong W. Efficacy of Proton Magnetic Resonance Spectroscopy in Neurological Diagnosis and Neurotherapeutic Decision Making. *NeuroRx*. 2005; 2: 197–214.
- 5.-Panigrahy A, Nelson M, Finlay J, Sposto R, Krieger M, Gilles F and Blüml S. Metabolism of diffuse intrinsic brainstem gliomas in children. *Neuro Oncol* 2008; 10:32-44.
- 6.- Alvarado A, Velasco V, García J, González MD, Torres B, Peña A and Alvarado M.<sup>1</sup>H Magnetic Resonance Spectroscopy demonstrates different metabolic features in Gliomatosis Cerebri. *Vitae* 2009; (37). [http:// caibco.ucv.ve / vitae /vitaetrentaysiete / artículos / imagenología/ archivos](http://caibco.ucv.ve/vitae/vitaetrentaysiete/articulos/imagenología/archivos).
- 7.- Pyhtinen J. Proton MR spectroscopy in gliomatosis cerebri. *Neuroradiology* 2000; 42: 612-615.
- 8.-Saraf-Lavi E, Bowen B, Pattany P, Sklar E, Murdoch J and Petito C. Proton MR Spectroscopy of Gliomatosis Cerebri: Case Report of Elevated Myoinositol with Normal Choline Levels. *Am J Neuroradiol* 2003; 24: 946-951.
- 9.-Mohana-Borges A, Imbesi S, Dietrich R, Alksne J, Amjadi D and Darius K. Role of Proton Magnetic Resonance Spectroscopy in the Diagnosis of Gliomatosis Cerebri: A Unique Pattern of Normal Choline but Elevated Myo-Inositol Metabolite Levels. *J Comput Assist Tomogr* 2004; 28: 103-105.
- 10.- Kararizou E, Likomanos D, Gkiatas K, Markou I, Triantafyllou N and Kararizos G. Magnetic resonance spectroscopy: a noninvasive diagnosis of gliomatosis cerebri. *Magn Reson Imaging* 2006; 24: 205-207.
- 11.-Uysal E, Erturk M, Yildirim H, Karatag O, Can M, Tanik C and Basak M. Multivoxel Magnetic Resonance Spectroscopy in Gliomatosis Cerebri. *Acta Radiol* 2005; 46: 621-624.
- 12.-Gutowski N, Gómez-Ansón B<sup>1</sup>, Torpey N, Revesz T, Miller D and Rudge P. Oligodendroglial gliomatosis cerebri: <sup>1</sup>H-MRS suggests elevated glycine/inositol levels. *Neuroradiology* 1999; 41:650-653.
- 13.-Movsas B, Li B, Babb J, Fowble B, Nicolaou N and Gonen O. Quantifying Radiation

Therapy-induced Brain Injury with Whole-Brain Proton MR Spectroscopy: Initial Observations. *Radiology* 2001; 221: 327-331.

14.-Fukushima Y, Nakagawa H and Tamura M. Combined surgery, radiation, and chemotherapy for oligodendroglial gliomatosis cerebri. *Br J Neurosurg* 2004; 18:306-310.

15.-Elshaikh M, Stevens G, Peereboom D, Cohen B, Prayson R, Lee S, Barnett G, and Suh J. Gliomatosis cerebri. Treatment results with radiotherapy alone. *Cancer* 95; 9: 2027-2031

16.-Sanson M, S. Cartalat-Carel, Taillibert S, Napolitano M, Djafari L, Cougnard J, Gervais H, Laigle F, Carpentier A, Mokhtari K, Taillandier L, Chinot O, Duffau H, Honnorat J, Hoang-Xuan K and Delattre J. Initial chemotherapy in gliomatosis cerebri. *Neurology* 2004; 63:270-275

17.-Glass M, Rasch K, Wiewrodt D, Weller M and Herrlinger U. Procarbazine and CCNU as Initial Treatment in Gliomatosis Cerebri. *Oncology* 2008; 75:182-185

18.-Piccirilli M, Landi A and Salvati M. Gliomatosis cerebri treatment in 11 elderly patients. *J Exp Clin Cancer Res* 2006; 25:183-187.

19.-Lodi R, Setola E, Tonon C, Ambrosetto P, Franceschi E, Crinò L, Barbiroli B, Cortelli P. Gliomatosis cerebri: clinical, neurochemical and neuroradiological response to temozolomide administration. *Magn Reson Imaging*. 2003; 21:1003-1007.

20.- Imamura K. Proton MR Spectroscopy of the Brain with a Focus on Chemical Issues. *Magn Res Med Sci* 2003; 2: 117-132.

21.- Galanaud D, Chinot O, Nicoli F, Confort-Gouny S, Le Fur Y, Barrie-Attarian M, Ranjeva J, Fuentès S, Viout P, Figarella-Branger D and Cozzone P. Use of proton magnetic resonance spectroscopy of the brain to differentiate gliomatosis cerebri from low-grade glioma. *J Neurosurg* 2003; 98: 269-276.

22.-Londoño A, Castillo M, Armao D, Kwock L and Suzuki K. Unusual MR Spectroscopic Imaging Pattern of an Astrocytoma: Lack of Elevated Choline and High myo-Inositol and Glycine Levels. *Am J Neuroradiol* 2003; 24: 942-945

23.-Bowen B. Glial Neoplasms without Elevated Choline-Creatine Ratios. *Am J Neuroradiol* 2003; 24:782-784.

24.-Castillo M, Smith J, and Kwock L. Correlation of Myo-inositol Levels and Grading of Cerebral Astrocytomas. *Am J Neuroradiol* 2000; 21: 1645-1649

25.-Bendszus M, Warmuth-Metz, Klein R, Burger R, Schichor C, Tonn J and Solymosi L. MR Spectroscopy in Gliomatosis Cerebri. *Am J Neuroradiol* 2000; 21: 375-380.

26.-Hattingen E, Raab P, Franz K, Zanella F, Lanfermann Hand Pilatus U. Myo-Inositol: a marker of reactive astrogliosis in glial tumors? *NMR in Biomedicine* 2007; 21: 233-241.

27.-Guzmán-de-Villoria J, Sánchez-González J, Muñoz L, Reig S, Benito C, García-Barreno and Desco M. <sup>1</sup>H MR Spectroscopy in the Assessment of Gliomatosis Cerebri. *Am J Roent* 2007; 188:710-714

28.-Lev M. Gliomatosis Cerebri has Normal Relative Blood Volume: Really?! Who cares? Should you? *Am J Neuroradiol* 2002; 23: 345-346

**NOTA:** Toda la información que se brinda en este artículo es de carácter investigativo y con fines académicos y de actualización para estudiantes y profesionales de la salud. En ningún caso es de carácter general ni sustituye el asesoramiento de un médico. Ante cualquier duda que pueda tener sobre su estado de salud, consulte con su médico o especialista.