





# etanephrin-producing adrenocortical carcinoma: a case report

*Carcinoma adrenocortical productor de metanefrinas: Reporte de un caso*

 Laura González-Fernández, MD<sup>1</sup>  Roberto José Añez-Ramos, MD<sup>1\*</sup>  Alejandra Maricel Rivas-Montenegro, MD<sup>1</sup>  Diego Muñoz Moreno, MD<sup>1</sup>  Juan Carlos Percovich-Hualpa, MD<sup>1,2</sup>

<sup>1</sup>Department of Endocrine and Nutrition, Gregorio Marañón General University Hospital; Madrid, Spain. <sup>2</sup>Quirónsalud South Hospital. Madrid, Spain.

Conflicts of interest: NONE declared

Funding sources: None

\*Correspondence author: Laura González-Fernández, Medical Doctor. Department of Endocrine and Nutrition, Gregorio Marañón General University Hospital; Madrid 28007, Spain. e-mail [lauragf\\_93@hotmail.com](mailto:lauragf_93@hotmail.com)

Received/Recibido: 02/24/2021 Accepted/Aceptado: 03/15/2021 Published/Publicado: 04/10/2021 DOI: <http://doi.org/10.5281/zenodo.5514202>

## Abstract

**A**drenocortical carcinoma is a rather infrequent neoplasm that mostly occurs with an autonomous secretion of steroids or steroid precursors. Previous cases have been reported with simultaneous production of metanephrines, but they were associated with intercurrent pheochromocytoma or mixed corticomedullar tumors. So far, only two cases of adrenocortical carcinoma that deliver medullar hormones had been published. We herein report a singular case of a 58-year-old man with a finding of an incidental adrenal mass that demonstrated metanephrine production in the hormonal study. Consequently, initial diagnosis of pheochromocytoma was established. Microscopic examination showed an adrenal mass with marked pleomorphism and frequent mitosis. Large areas of coagulative necrosis were interspersed within the tumour. After immunohistochemistry staining there was a high expression of Ki67 (>70%) showing highly proliferative behaviour. Both cytokeratin AE1/AE3 and vimentin were positive, synaptophysin and chromogranin were negative. The surgical margins were free. Given these features, a diagnosis of metanephrin-producing adrenocortical carcinoma was done.

**Keywords:** metanephrine-producing adrenocortical carcinoma; mixed corticomedullar tumours; pheochromocytoma; metanephrine; mitotane.

## Resumen

**E**l carcinoma adrenocortical es una neoplasia infrecuente que ocurre mayoritariamente con una secreción autónoma de esteroides y precursores esteroideos. Reportes previos han mostrado la producción de metanefrinas, pero generalmente asociados a feocromocitoma intercurrente o tumores corticomedulares mixtos. Hasta ahora, solo dos casos de carcinomas adrenocorticales liberadores de hormonas medulares han sido publicados. Aquí reportamos el caso singular de un hombre de 58 años de edad con hallazgos incidental de una masa adrenal que mostró la producción de metanefrinas en el estudio hormonal. Inicialmente se estableció el diagnóstico de feocromocitoma. Pero el análisis microscópico mostró una masa adrenal con marcado pleomorfismo y mitosis frecuentes, amplias zonas de necrosis coagulativa dentro del tumor. Tras el análisis2 inmunohistoquímico se observó una altas expression de Ki67 (>70%) mostrando una alta tasa proliferativa. Tanto la citoqueratina AE1/AE3 y vimentina fueron positivos, sinaptofisina y cromogranina negativa. Los márgenes quirúrgicos estuvieron libres. Dadas estas características, se realizó el diagnóstico de carcinoma adrenocortical productor de metanefrinas

**Keywords:** carcinoma adrenocortical productor metanefrinas; tumores corticomedulares mixtos; feocromocitomas; metanefrinas; mitotano.

**A**drenocortical carcinoma (ACC) is a rather infrequent neoplasm that mostly occurs with an autonomous secretion of steroids or steroid precursors<sup>1</sup>. Previous cases have been reported with simultaneous production of metanephrines, but they were associated with intercurrent pheochromocytoma or mixed corticomedullary tumors<sup>2</sup>. So far, only two cases of ACC that deliver medullar hormones had been published<sup>3,4</sup>. We herein present another case of metanephrine-producing ACC.

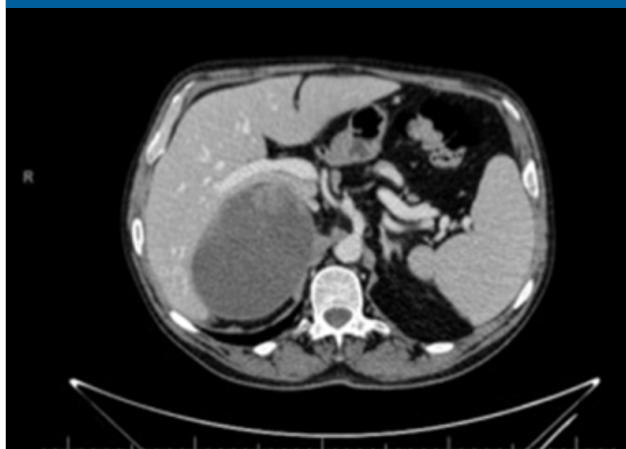
### Case Report

A 58-year old male with a history of arterial hypertension, dyslipidaemia, ischemic heart disease and diverticulosis presented in our clinic with an incidental finding of an adrenal mass. The patient denied neither drug intake nor tobacco or alcohol consumption. His current medications included lisinopril, atorvastatin, acetyl salicylic acid and allopurinol.

In a previous study performed by the Internal Medicine Department an elevation of vanilylmandelic, hydroxy-indole-acetic acid and metanephrins was noted. After doing a control Computed Tomography (CT) scanning, an increase in 1 cm in the adrenal mass was observed during the year under study.

Once growth was noted, the patient was transferred to Endocrinology Department where a hormonal functioning study was performed. After analysis, only urine metanephrins were elevated 2-fold time more than the normality interval. An (131) I-meta-iodobenzylguanidine gammagraphy was done ruling out chromaffin tumoral cellularity. A new abdominal-pelvic CT scan was performed one year later due to patient's self-neglect, showing a significant growth of the right adrenal mass whose maximum diameter was 12 cm (Figure 1).

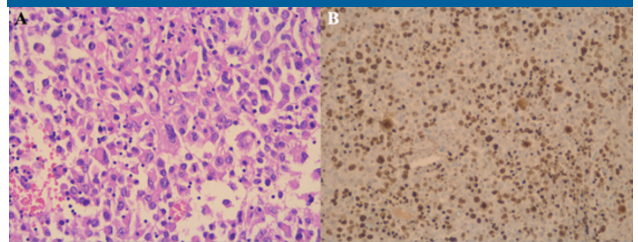
**Figure 1. CT abdominopelvic scan. Right hypodense adrenal mass of 12 x 90 cm in diameter with septa within the lesion and a thick wall surrounding it.**



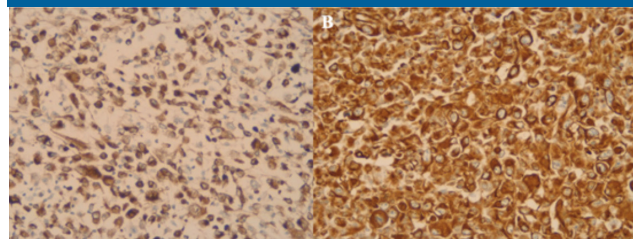
Given the possible diagnosis of pheochromocytoma, pre-treatment with doxazosine 8 mg prior to right laparoscopic suprarenalectomy was performed. There were not any postoperative incidences after surgery.

Under microscopic examination there was an adrenocortical mass which showed a marked pleomorphism with abundant atypical cells and frequent mitosis (Figure 2; Panel A), large areas of coagulative necrosis were interspersed within the tumour. After immunohistochemistry staining there was a high expression of Ki67 (>70%) showing highly proliferative behaviour (Figure 2; Panel B). Both cytokeratin AE1-A3 and vimentin were positive (Figure 3), synaptophysin and chromogranin were negative, the margins were free. Given these features, a diagnosis of metanephrin-producing ACC was done; staging test was completed with a chest CT that showed no lesions.

**Figure 2. Histological features of the adrenocortical tumour. A. Cell pleomorphism and marked mitotic activity with atypical forms (H&Ex40). B. High Ki67 expression (70%).**



**Figure 3. Immunohistochemical characterisation of the neoplasm. A. Positive staining for cytokeratin AE1-A3 demonstrating its epithelial origin. B. Positive vimentin staining.**



Postoperative urine analysis exhibited a persistent elevation of both vanilylmandelic acid and hydroxy-indole-acetic acid whereas metanephrins were normalized. During patient study, neither androgen, dehydroepiandrosterone sulphate (DHEA-S) nor cortisol levels were ever elevated.

After suprarenalectomy, adjuvant treatment with mitotane was initiated. Adjuvant therapy was started within six weeks after adrenalectomy as updated guidelines recommend. A dose of 2-3g daily of mitotane was initiated and increased rapidly and gradually tapered until plasma levels were reached within the therapeutic window.

Corticotherapy with hydrocortisone was added too. The patient presented good initial tolerance to the drug. However, 12 months after starting therapy he developed oral and esophageal aphtae for which he did not consult at first, leading to food intolerance and progressive weight loss. Finally, he went to the emergency department where Internal Medicine physicians withdrew the drug given the

suspected diagnosis of mucositis. This was treated and oral nutritional supplements were provided. The patient regained adequate weight and nutritional status. Mitotane was not reintroduced later due to patient refusal. To date, the patient has no signs of disease persistence or recurrence.

**A**drenocortical carcinoma is a rare disease, with an estimated incidence of 1-2 cases per million. More than 95% of patients present an autonomous secretion of steroids or steroid precursors<sup>1</sup>. Despite this, there are only two cases of metanephrin-producing adrenocortical carcinoma in literature. The first reported case was a 28-year old lady with clinical and biochemical features of pheochromocytoma (paroxysmal hypertension and palpitations associated with raised urinary vanilylmandelic acid), but with histological criteria only compatible with ACC<sup>4</sup>. The second case was a 35-year old female with an initial presentation of pheochromocytoma (episodic palpitations accompanied by sweating and flushing, with urine metanephrins raised above the normal range)<sup>3</sup>. In this particular patient, we found that metanephrin level was not elevated two-fold the superior limit as a diagnostic condition<sup>5</sup>.

Although extremely infrequent, there are several reports of mixed corticomedullary tumours<sup>2,6-9</sup>. They are single mass neoplasms composed by both adrenocortical and chromaffin cells. Clinical features are compatible with both hormonal hypersecretion syndromes, being Cushing symptoms and signs far more frequent<sup>2</sup>. Histologically they are composed by both types of cells interspersed each other. This is a differential feature that distinguishes mixed corticomedullary tumors from the coincidence of an adrenal adenoma and a pheochromocytoma in the same gland<sup>10,11</sup>, that have both cellular components clearly demarcated.

The case we herein present is not a mixed neoplasm as previously mentioned, since both histopathological and immunohistochemical findings only revealed adrenocortical features like positivity to vimentin and cytokeratin AE1-A3, and negative marking for chromogranin A. Clinical findings were however more related to a pheochromocytoma (arterial hypertension that was interrupted after surgery, elevated 24h urine metanephrins and the radiologic identification of a heterogeneous, haemorrhagic adrenal mass).

In addition to this, it should be noted that due to histological examination the patient was appropriately diagnosed and could therefore receive the adequate treatment for his disease. Thus, adjuvant mitotane was initiated after performing surgery as guidelines recommend. These guidelines suggest adjuvant mitotane treatment in those

patients without macroscopic residual tumor after surgery but who have perceived high risk of recurrence (stage III, or R1 resection, or Ki67 >10%)<sup>12</sup>. In this case, the tumor had a Ki67 >70%, a powerful predictor of recurrence and therefore treatment with mitotane was indicated.

The description of mixed adrenocortical with both cortical and medullary hypersecretion and expression is scarce but present in literature. Nevertheless, after a thorough search in previous literature we only found two other cases of metanephrin-producing ACC without pheochromocytoma component<sup>3,4</sup>. To our knowledge this is the third case of such entity and we consider relevant to notify this. In conclusion we present an extraordinary case of metanephrin-producing ACC. Histological study is mandatory to correctly diagnose this entity, and these pathological features may lead to initiate proper adjuvant therapy such as mitotane.

## References

1. Fassnacht M, Eder M, Allolio B. Best Practice & Research Clinical Endocrinology & Metabolism Clinical management of adrenocortical carcinoma. *Best Pract Res Clin Endocrinol Metab.* 2009;23(2):273-289. doi:10.1016/j.beem.2008.10.008
2. Alsabek MB, Alhmaidi R, Ghazzawi B, Hamed G, Alseoudi A. Mixed corticomedullary adrenal carcinoma – case report: Comparison in features, treatment and prognosis with the other two reported cases. *Int J Surg Case Rep.* 2017;31:254-261. doi:10.1016/j.ijscr.2017.01.010
3. Bagchi PK, Bora SJ, Barua SK, Puthenveetil RT. Giant adrenal tumor presenting as Cushing's syndrome and pheochromocytoma: A case report. *Asian J Urol.* 2015;2(3):182-184. doi:10.1016/j.ajur.2015.06.007
4. Ni H, Htet A. Adrenal cortical carcinoma masquerading as pheochromocytoma: A case report. *Ecancermedscience.* 2012;6(1):10-15. doi:10.3332/ecancer.2012.277
5. Lenders JWM, Duh QY, Eisenhofer G, et al. Pheochromocytoma and paraganglioma: An endocrine society clinical practice guideline. *J Clin Endocrinol Metab.* 2014;99(6):1915-1942. doi:10.1210/jc.2014-1498
6. Alexandraki KI, Michail OP, Nonni A, et al. Corticomedullary mixed adrenal tumor: Case report and literature review. *Endocr J.* 2009;56(6):817-824. doi:10.1507/endocrj.K09E-010
7. Michalopoulos N, Pazaitou-Panayiotou K, Boudina M, Papavramidis T, Karayannopoulou G, Papavramidis S. Mixed corticomedullary adrenal carcinoma. *Surg Today.* 2013;43(11):1232-1239. doi:10.1007/s00595-012-0458-4
8. Turk AT, Asad H, Trapasso J, Perilli G, Livolsi VA. Mixed corticomedullary carcinoma of the adrenal gland: A case report. *Endocr Pract.* 2012;18(3):37-42. doi:10.4158/EP11222.CR
9. Donatini G, Van Slycke S, Aubert S, Carnaille B. Corticomedullary mixed tumor of the adrenal gland - A clinical and pathological chameleon: Case report and review of literature. *Updates Surg.* 2013;65(2):161-164. doi:10.1007/s13304-011-0132-1
10. Crisis HC, Adenoma AA. Syndrome with Cortical Crisis and Mixed. 1968.
11. Hwang WR, Ma WY, Tso AL, Pan CC, Chang YH, Lin H Da. Pheochromocytoma and adrenocortical adenoma in the same gland. *J Chinese Med Assoc.* 2007;70(7):289-293. doi:10.1016/S1726-4901(07)70007-2
12. Fassnacht M, Dekkers OM, Else T, et al. European society of endocrinology clinical practice guidelines on the management of adrenocortical carcinoma in adults, in collaboration with the European Network for the study of adrenal tumors. *Eur J Endocrinol.* 2018;179(4):G1-G46. doi:10.1530/EJE-18-0608