

Ultrasonography Profiles in Patients with Asymptomatic Hyperuricemia

Perfiles de ecografía en pacientes con hiperuricemia asintomática

Awalia^{1a}, Tigor Yeheskiel^{2b}, Rosy Setiawati^{3b}, Paulus Rahardjo^{4b}, Arinditia Triasti Putri^{5c}

SUMMARY

Backgrounds: Asymptomatic hyperuricemia (AHU) patients mostly do not develop gouty arthritis. The best procedure to investigate whether they have MSU deposition has not been established. We report our preliminary study about ultrasonography on AHU patients.

Methods: In this cross-sectional study, we enrolled asymptomatic hyperuricemia patients who matched the gout classification criteria of the American College of Rheumatology (ACR)/European League Against Rheumatism (EULAR) (2015). Six joints were examined per patient by ultrasonography including the first metacarpophalangeal (MCP) joints, first metatarsophalangeal (MTP) joints, and trochlear knees to determine pathological findings which may demonstrate clinically silent urate deposits in asymptomatic hyperuricemia individuals.

Results: Average age was 49.27±12.35 years old. The average serum uric acid level was 7.64±1.67 mg/dL. Ultrasonography of the first MCP showed joint

effusion in 11 patients (73 %), double contour in 10 patients (66 %), tophus in 1 patient (6 %), snowstorm appearance in 1 patient, hypervascularization in 1 patient, and synovitis in 3 patients (20 %). Four patients revealed normal features. First MTP joints showed 13 joint effusions (86 %), double contours in 13 patients (86 %), 1 bone erosion (6 %), 3 tophi (20 %), and 2 synovitis (13 %). There was no hypervascularization or snowstorm appearance found. Two patients showed normal USG. From trochlear knees, we found 1 joint effusion (6 %), and 1 double contour (6 %), and 14 patients were normal.

Conclusions: Abnormal ultrasound findings such as double contour sign and tophi were detected in asymptomatic hyperuricemia. The most frequent joint affected was the first MTP. Whether this result influences our decision to initiate urate-lowering therapy and anti-inflammatory treatment is still to be determined.

Keywords: Asymptomatic hyperuricemia, joints, ultrasonography.

DOI: <https://doi.org/10.47307/GMC.2023.131.s2.3>

ORCID: 0000-0002-4232-384X¹

ORCID: 0000-0001-7947-9920²

ORCID: 0000-0001-8442-7287³

ORCID: 0000-0002-1821-4811⁴

ORCID: 0000-0001-9690-639X⁵

^aDivision of Rheumatology, Department of Internal Medicine, Faculty of Medicine, Airlangga University, Dr. Soetomo Teaching Hospital, Surabaya, Indonesia

Recibido: 28 de diciembre 2022

Aceptado: 11 de enero 2023

^bDepartment of Radiology, Faculty of Medicine, Airlangga University, Dr. Soetomo Teaching Hospital, Surabaya, Indonesia

^cDepartment of Internal Medicine, Faculty of Medicine, Airlangga University, Dr. Soetomo Teaching Hospital, Surabaya, Indonesia

*Corresponding author: Awalia

Division of Rheumatology, Department of Internal Medicine, Faculty of Medicine, Airlangga University, Dr. Soetomo Teaching Hospital, Jl. Mayjend Prof. Dr. Moestopo No. 6-8, Airlangga, Gubeng, Surabaya, East Java 60286, Indonesia

Phone: +628123525982

E-mail: awalia_nov74@yahoo.com

RESUMEN

Antecedentes: Los pacientes con hiperuricemia asintomática (AHU) en su mayoría no desarrollan artritis gotosa. No se ha establecido el mejor procedimiento para investigar si tienen depósito de MSU. Presentamos nuestro estudio preliminar sobre ultrasonografía en pacientes de AHU.

Métodos: En este estudio transversal, reclutamos pacientes con hiperuricemia asintomática que coincidían con los criterios de clasificación de gota del Colegio Americano de Reumatología (ACR)/Liga Europea Contra el Reumatismo (EULAR) (2015). Se examinaron seis articulaciones por paciente mediante ultrasonografía, incluidas las primeras articulaciones metacarpofalángicas (MCP), las primeras articulaciones metatarsofalángicas (MTP) y las rodillas trocleares para determinar los hallazgos patológicos que pueden demostrar depósitos de urato clínicamente silenciosos en individuos asintomáticos con hiperuricemia.

Resultados: La edad promedio fue de $49,27 \pm 12,35$ años. El nivel medio de ácido úrico sérico fue de $7,64 \pm 1,67$ mg/dL. La ecografía de la primera MCP mostró derrame articular en 11 pacientes (73 %), doble contorno en 10 pacientes (66 %), tofo en 1 paciente (6 %), aspecto de tormenta de nieve en 1 paciente, hipervascularización en 1 paciente y sinovitis en 3 pacientes (20 %). Cuatro pacientes revelaron características normales. Las primeras articulaciones MTP presentaron 13 derrames articulares (86 %), doble contorno en 13 pacientes (86 %), 1 erosión ósea (6 %), 3 tofos (20 %) y 2 sinovitis (13 %). No se encontró hipervascularización ni apariencia de tormenta de nieve. Dos pacientes mostraron USG normal. De las rodillas trocleares encontramos 1 derrame articular (6 %), 1 doble contorno (6 %) y 14 pacientes eran normales.

Conclusiones: En la hiperuricemia asintomática se detectó un hallazgo ecográfico anormal como signo de doble contorno y tofos. La articulación más frecuentemente afectada fue la primera MTP. Queda por determinar si este resultado influye en nuestra decisión de iniciar un tratamiento hipouricemiente y un tratamiento antiinflamatorio.

Palabras clave: Hiperuricemia asintomática, articulaciones, ultrasonografía.

INTRODUCTION

Asymptomatic hyperuricemia is defined as elevated uric acid levels with no clinical symptoms and is commonly viewed as an entity

that should not be treated (1,2). Hyperuricemia may result from increased production or decreased excretion of uric acid (3). Many individuals with hyperuricemia are clinically asymptomatic, with 5 %-18.83 % estimated to develop gout later (4). The disease burden of hyperuricemia is increasing, especially in high-income countries and economically developing worlds with urban lifestyles (3,5). The prevalence of hyperuricemia in the United States was 21.4 %, while in China the prevalence was 13.3 % (6,7). Serum uric acid levels are also associated with all-cause and cardiovascular mortality, independent of other cardiovascular risk factors (8).

Advanced imaging and microscopy studies have shown that monosodium urate (MSU) crystals are present in many people with hyperuricemia with no history of flares and no clinical evidence of tophi (9). Monosodium urate deposition on cartilage is an early step in developing gout. This deposition may also lead to direct mechanical damage of the joint, predisposing it to degenerative arthritis. Additionally, occultly deposited MSU may induce low-level inflammation, with systemic consequences (10). A single-center retrospective cohort study of 5 899 Japanese adults with asymptomatic hyperuricemia without comorbidities had a significant risk of developing cardiometabolic conditions (11). The imaging technique, such as joint ultrasonography may demonstrate clinically silent urate deposits in asymptomatic hyperuricemia individuals (12,13). Ultrasound (US) has advantages over other imaging modalities including the lack of ionizing radiation, non-invasive, relatively cost, patient acceptability, and ease of access (14). Pathological findings on ultrasonography like tophi in tendons and synovium, double contour sign in the first metatarsophalangeal joint, and increased vascularity were documented in asymptomatic hyperuricemia patients (15-17).

To date, there is still no consensus approved for urate-lowering therapy indication in asymptomatic hyperuricemia individuals (18). The latest systematic review study has found evidence that asymptomatic hyperuricemia should be treated only under specific circumstances (19). This is different from Japan where asymptomatic hyperuricemia patients are actively treated to prevent coronary events, CKD, and arterial

hypertension (20). In this study, we analyzed the joint ultrasonography results from patients who were diagnosed with asymptomatic hyperuricemia to evaluate MSU crystal deposition and lesions in joints in considering whether to initiate urate-lowering therapy and anti-inflammatory treatment.

METHODS

Study design and participant

This was a descriptive study using a cross-sectional approach. Patients aged 30-70 years old, diagnosed with asymptomatic hyperuricemia in the internal medicine outpatient clinic in Dr. Soetomo Teaching Hospital from February 1st to April 30th, 2015, were eligible for this study. The required inclusion criteria for patients with asymptomatic hyperuricemia matched the gout classification criteria of the American College of Rheumatology (ACR)/European League Against Rheumatism (EULAR) (2015). The exclusion criteria for patients with gout were prior diagnosis of other crystal-related arthropathies, patients with a history of fracture of upper or lower limbs, dislocation, and patients with rheumatoid arthritis and osteomyelitis. Urate levels in fasting serum in asymptomatic hyperuricemia patients were greater than 7 mg/dL for men, and >6 mg/dL for women, and this was confirmed at least twice. All the following data, including demographics (i.e., sex, age, and uric acid level) were collected. The first metacarpophalangeal, first metatarsophalangeal, and trochlear knee were assessed using ultrasonography for each patient, which corresponds to 6 screened joints per patient. Written informed consent was obtained from all patients, and the study protocol was approved by the ethics committee of the Dr. Soetomo Teaching Hospital Surabaya, Indonesia (238/Panke KKE/IV/2015).

US Assessment

The US examination was performed by skilled sonographers who had more than 10 years of experience in the musculoskeletal US in Dr. Soetomo Teaching Hospital. Hitachi Hi Vision Avius diagnostic apparatus (probe frequency 5-10

MHz) was used for the US examination. US gout lesion in asymptomatic hyperuricemia patients was evaluated in first metacarpophalangeal-metatarsophalangeal joints and trochlear knee for double countersign (DCS), tophi, joint effusion, bone erosion, vascularization enhancement on doppler, and snowstorm appearance.

Statistical Analysis

The results of this study were processed on SPSS software version 24 (SPSS Inc., Chicago, IL, USA) and expressed as descriptive data. All continuous data were presented in mean \pm standard deviation (SD). Meanwhile, categorical data were presented in numbers and percentages.

RESULTS

Clinical Characteristics of the Study Population

The clinical characteristics of the patients are shown in Table 1. The study included 15 patients who came to the internal medicine outpatient clinic from February 1st to April 30th, 2015. Patient's average age was 49.27 ± 12.35 years old, predominated by those who were 51-60 years old (46.67 %), followed by the 31-40 years old group (26.67 %), and respectively 13.33 % for 41-50- and 61-70-years old group. The number of female patients (60 %) was greater than male patients (40 %). The laboratory findings of uric acid level with an average of 7.64 ± 1.67 mg/dL.

Table 1. Clinical characteristics of asymptomatic hyperuricemia patients

Characteristics	n (%)
Gender	
Male	6 (40)
Female	9(60)
Age, mean \pm SD (years old)	49.27 \pm 12.35
31-40	4 (26.67)
41-50	2 (13.33)
51-60	7 (46.67)
61-70	2 (13.33)
Laboratory findings	
Uric Acid (mg/dL)	7.64 \pm 1.67

ULTRASONOGRAPHY PROFILES

US Findings in Patients with Asymptomatic Hyperuricemia

The Ultrasound findings of the first MCP for asymptomatic hyperuricemia patients are shown in Figure 1. Joint effusion (73%), double

contour sign (66%), and synovitis (20%) were documented on ultrasound of the first MCP. Power Doppler ultrasound detected increased vascularity in 1 patient (6%), as well as tophus and snowstorm appearance documented in 1 patient.

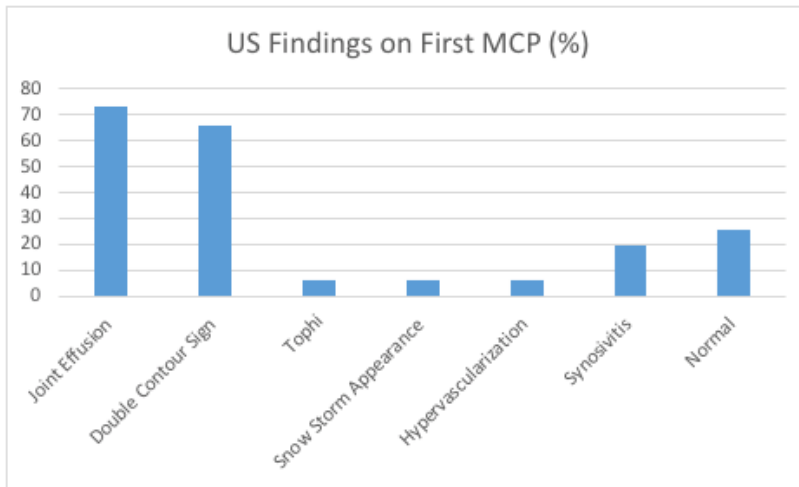


Figure 1. Ultrasound findings on first metacarpophalangeal joints.

Meanwhile, US findings of first MTP joints showed 13 joint effusions (86%), double contour in 13 patients (86%), 1 bone erosion (6%), 3 tophi (20%), and 2 synovitis (13%) as shown on

Figure 2. There was no hypervascularization nor snowstorm appearance found, and two patients had normal US evaluation of the first MTP.

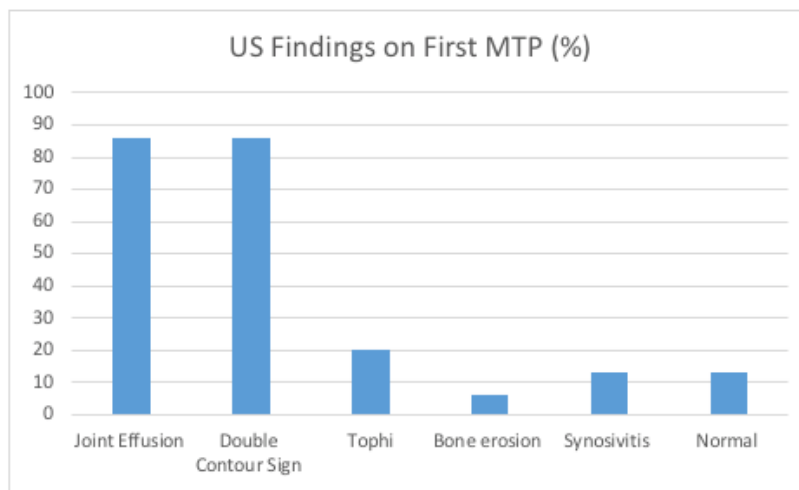


Figure 2. Ultrasound findings on first metatarsophalangeal joints.

From trochlear knees, we found 1 joint effusion (6%), 1 double contour (6%), and 14 patients

were normal as shown on Figure 3.

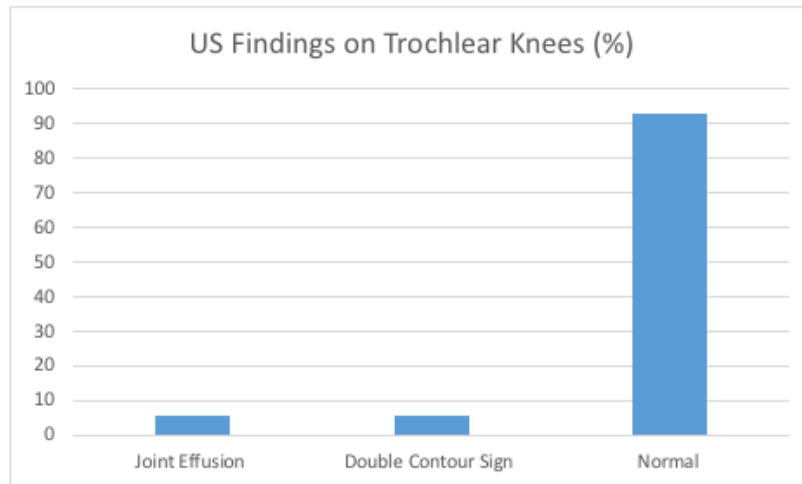


Figure 3. Ultrasound findings on trochlear knees.

DISCUSSION

The demographic of this study shows that the average age of asymptomatic hyperuricemia patients in this study was 49.27 years old, which were correspond to a cross-sectional study of gout and asymptomatic Japanese patients (21). The total sample of our study was limited due to a rare case found in our tertiary hospital, where AHU cases are usually found in first-level referral health facilities. Our study was aimed at demonstrating a wide spectrum of subclinical structural damage in asymptomatic individuals with hyperuricemia. Some structural changes in joints can be seen on ultrasound. Previous studies have confirmed that asymptomatic hyperuricemia and gout may share the same ultrasonic appearance (22-24).

Characteristic US abnormalities of MSU crystal deposits were presented as double contour sign (DCS), hyperechoic aggregates (HAG), and tophi in people with gout and asymptomatic hyperuricemia. Those features of MSU deposition are associated with clinically evident

foot-related pain, impairment, and functional disability. Other than those features, soft tissue inflammation (synovial lesions i.e., synovial hypertrophy and synovitis) and bone erosion are also detected in gout and asymptomatic hyperuricemia (13,25). Lower limb joints are more affected in the early stage of gout, especially the first MTP than upper limb joints including hands, wrist, and elbow (13). In this study, we found double contour signs were documented in the ultrasound of the first MCP (66%) and first MTP (86%), respectively. It is in line with the study conducted in Mexico, the prevalence of the double contour sign in the first MTP joints was higher in asymptomatic hyperuricemia than in normo-uricemia patients (25% vs 0%) (26). Tophi formation was found in the first MCP (6%) and first MTP (20%) individuals included in our study, like the study conducted by Pineda et al. (26). Our findings also supported by the systematic review and meta-analysis study showed the most common site scanned was first MTP and the common lesion reported the double contour followed by tophus in asymptomatic hyperuricemia (17).

A study conducted in China showed that HAG is the US sign for early MSU crystal deposition, while DCS and tophi are for chronic gout. DCS and tophi were correlated with bone erosion which made irreversible injuriousness in gout (13). Previous research suggested that MSU deposition in joints is a crucial factor in gouty arthritis attacks. Urate crystal deposits can lead to chronic inflammatory conditions that may trigger a cellular inflammatory response. Asymptomatic hyperuricemia is associated with cardiovascular, renal, and metabolic disease. Evidence suggests that urate-lowering may reduce comorbid risk in patients with asymptomatic hyperuricemia, and timely ULT may also minimize DCS and tophi in gout patients (10,13). Many guidelines for the management of hyperuricemia and gout from various countries show conflicting policies regarding asymptomatic hyperuricemia. According to ACR 2020 and EULAR 2016 guidelines for asymptomatic hyperuricemia patients with no prior gout flares or subcutaneous tophi, they conditionally recommend against initiating any pharmacologic ULT. But Japanese guideline recommends pharmacological treatment using ULT besides lifestyle modification if plasma uric acid level ≥ 9 mg/dL in people without complications such as kidney disease, urolithiasis, hypertension, ischemic heart disease, diabetes mellitus, and metabolic syndrome. Taiwanese guideline also recommends starting ULT treatment if the plasma uric acid level is ≥ 9 mg/dL for people with comorbidity and ≥ 10 mg/dL for those without any comorbidity (27-30).

The limitation of our study was no interventional trials to investigate if urate-lowering therapy has positive effects on those patients with asymptomatic hyperuricemia. We did not follow and monitor the clinical condition as well (i.e., development of joint pain/arthritis later on), nor the ultrasound sequence after several months/years.

CONCLUSION

In conclusion, our study contributes some evidence that asymptomatic hyperuricemia demonstrated a wide of structural damages in the evaluation of ultrasonography musculoskeletal. The US seems to be a suitable tool to early detect

these structural changes. Our observations might have an impact on further treatment decisions, such as performing musculoskeletal US of predilection joints in patients with asymptomatic hyperuricemia. When to initiate urate-lowering therapy is still a big question, especially in patients with a high risk of pathological specific findings of gout by the US and those with other cardiovascular and metabolic comorbidities.

REFERENCES

1. Chalès G. How should we manage asymptomatic hyperuricemia? *Jt Bone Spine*. 2019;86(4):437-443.
2. Kanellis J, Feig DI, Johnson RJ. Does asymptomatic hyperuricaemia contribute to the development of renal and cardiovascular disease? An old controversy renewed. *Nephrology*. 2004;9(6):394-399.
3. Lijun Li, Yipeng Z, Changchun Z. Update on the epidemiology, genetics, and therapeutic options of hyperuricemia. *Am J Transl Res*. 2020;12(7):3167-3181.
4. Liu F, Chen S, Hu Z, Chen J, Jiang L, Qu S, et al. Musculoskeletal ultrasound features-based scoring system can evaluate the severity of gout and asymptomatic hyperuricaemia. *Ther Adv Musculoskelet Dis*. 2021;13:1-8.
5. Singh G, Lingala B, Mithal A. Gout and hyperuricaemia in the USA: Prevalence and trends. *Rheumatology*. 2019;58(12):2177-2180.
6. Zhu Y, Pandya BJ, Choi HK. Prevalence of gout and hyperuricemia in the US general population: The National Health and Nutrition Examination Survey 2007-2008. *Arthritis Rheum*. 2011;63(10):3136-3141.
7. Liu R, Han C, Wu D, Xia X, Gu J, Guan H, et al. Prevalence of hyperuricemia and gout in mainland China from 2000 to 2014: A systematic review and meta-analysis. *Biomed Res Int*. 2015.
8. Maloberti A, Giannattasio C, Bombelli M, Desideri G, Cicero AFG, Muiesan ML, et al. Hyperuricemia and Risk of Cardiovascular Outcomes: The Experience of the URRAH (Uric Acid Right for Heart Health) Project. *High Blood Press Cardiovasc Prev*. 2020;27(2):121-128.
9. Dalbeth N, Stamp L. Hyperuricaemia and gout: Time for a new staging system? *Ann Rheum Dis*. 2014;73(9):1598-1600.
10. Yip K, Cohen RE, Pillinger MH. Asymptomatic hyperuricemia: Is It really asymptomatic? *Curr Opin Rheumatol*. 2020;32(1):71-79.
11. Kuwabara M, Niwa K, Hisatome I, Nakagawa T, Roncal-Jimenez CA, Andres-Hernando A, et al.

- Asymptomatic Hyperuricemia Without Comorbidities Predicts Cardiometabolic Diseases Five-Year Japanese Cohort Study. *Hypertension*. 2017;69(6):1036-1044.
12. Zhang Q, Gao F, Sun W, Ma J, Cheng L, Li Z. The diagnostic performance of musculoskeletal ultrasound in gout: A systematic review and meta-analysis. *PLoS One*. 2018;13(7):1-14.
 13. Cao L, Zhao T, Xie C, Zheng S, Wan W, Zou H, et al. Performance of Ultrasound in the Clinical Evaluation of Gout and Hyperuricemia. *J Immunol Res*. 2021;2021:7.
 14. Chowalloor P V, Keen HI. A systematic review of ultrasonography in gout and asymptomatic hyperuricaemia. *Ann Rheum Dis*. 2013;72(5):638-645.
 15. Puig JG, De Miguel E, Castillo MC, Rocha AL, Martínez MA, Torres RJ. Asymptomatic hyperuricemia: Impact of ultrasonography. *Nucleosides, Nucleotides and Nucleic Acids*. 2008;27(6-7):592-595.
 16. Reuss-Borst MA, Pape CA, Tausche AK. Hidden gout- Ultrasound findings in patients with musculoskeletal problems and hyperuricemia. *J Korean Phys Soc*. 2014;3(1):1-7.
 17. Stewart S, Maxwell H, Dalbeth N. Prevalence and discrimination of OMERACT-defined elementary ultrasound lesions of gout in people with asymptomatic hyperuricaemia: A systematic review and meta-analysis. *Semin Arthritis Rheum*. 2019;49(1):62-73.
 18. Paul BJ, Anoopkumar K, Krishnan V. Asymptomatic hyperuricemia: Is it time to intervene? *Clin Rheumatol*. 2017;36(12):2637-2644.
 19. Brucato A, Cianci F, Carnovale C. Management of hyperuricemia in asymptomatic patients: A critical appraisal. *Eur J Intern Med*. 2020;74(January):8-17.
 20. Hakoda M, Kasagi F. Increasing trend of asymptomatic hyperuricemia under treatment with urate-lowering drugs in Japan. *Mod Rheumatol*. 2019;29(5):880-884.
 21. Koto R, Nakajima A, Horiuchi H, Yamanaka H. Real-world treatment of gout and asymptomatic hyperuricemia: A cross-sectional study of Japanese health insurance claims data. *Mod Rheumatol*. 2020;31(1):261-269.
 22. De Miguel E, Puig JG, Castillo C, Peiteado D, Torres RJ, Martín-Mola E. Diagnosis of gout in patients with asymptomatic hyperuricaemia: A pilot ultrasound study. *Ann Rheum Dis*. 2012;71(1):157-158.
 23. Ottaviani S, Allard A, Bardin T, Richette P. An exploratory ultrasound study of early gout. *Clin Exp Rheumatol*. 2011;29(5):816-821.
 24. Howard RG, Pillinger MH, Gyftopoulos S, Thiele RG, Swearingen CJ, Samuels J. Reproducibility of musculoskeletal ultrasound for determining monosodium urate deposition: Concordance between readers. *Arthritis Care Res*. 2011;63(10):1456-1462.
 25. Stewart S, Dalbeth N, Vandal AC, Allen B, Miranda R, Rome K. Ultrasound features of the first metatarsophalangeal joint in gout and asymptomatic hyperuricemia: Comparison with normouricaemic individuals. *Arthritis Care Res*. 2016:1-38.
 26. Pineda C, Amezcua-Guerra LM, Solano C, Rodriguez-Henríquez P, Hernández-Díaz C, Vargas A, et al. Joint and tendon subclinical involvement suggestive of gouty arthritis in asymptomatic hyperuricemia: An ultrasound controlled study. *Arthritis Res Ther*. 2011;13(1):1-7.
 27. Richette P, Doherty M, Pascual E, Barskova V, Becce F, Castañeda-Sanabria J, et al. 2016 updated EULAR evidence-based recommendations for the management of gout. *Ann Rheum Dis*. 2017;76(1):29-42.
 28. FitzGerald JD, Dalbeth N, Mikuls T, Brignardello-Petersen R, Guyatt G, Abeles AM, et al. 2020 American College of Rheumatology Guideline for the Management of Gout. *Arthritis Care Res*. 2020;72(6):744-760.
 29. Kohagura K, Sato Y, Taniguchi A, Masuda I, Moriwaki Y, Yamamoto T. Japanese Guideline for Hyperuricemia and Gout. 2020;44:1-40.
 30. Yu KH, Chen DY, Chen JH, Chen SY, Chen SM, Cheng TT, et al. Management of gout and hyperuricemia: Multidisciplinary consensus in Taiwan. *Int J Rheum Dis*. 2018;21(4):772-787.